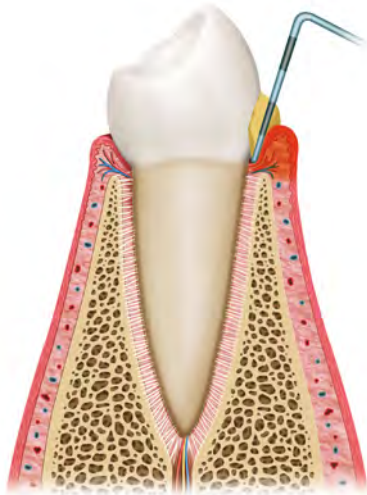
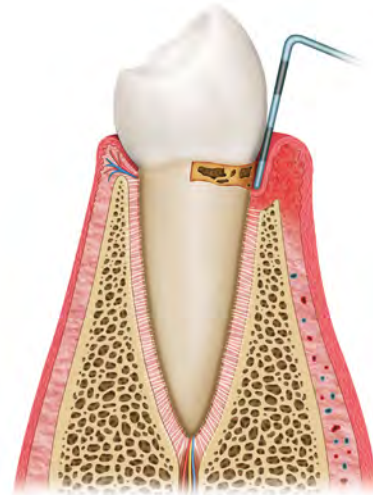

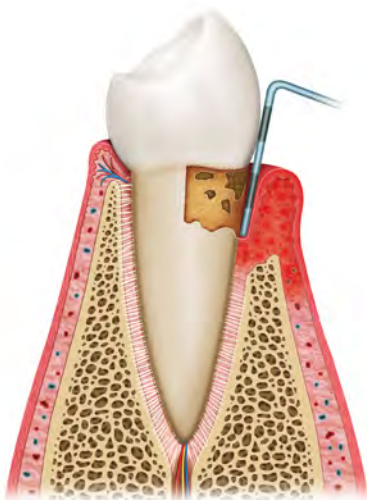
Stages of Periodontal Diseases



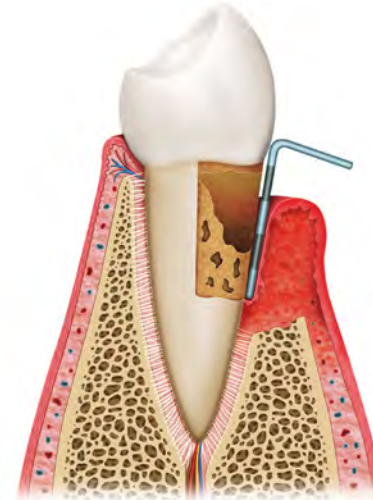
Gingivitis – superficial redness, swelling and inflammation (right) caused by dental plaque compared to healthy gums and supporting tissue (above)



Gingivitis and mild periodontitis – initial destruction of the supporting bone and periodontal ligament leading to the formation of pockets



Gingivitis and moderate periodontitis - progression of the disease with further destruction of the supporting bone and deepening of pockets



Gingivitis, severe periodontitis and recession - severe destruction of bone and periodontal ligament leads to tooth mobility and eventual loss

Note that the left hand side of each image illustrates healthy gums and supporting tissues.